

Postoperative assessment of diode laser zinc oxide eugenol and mineral trioxide aggregate pulpotomy procedures in children: A comparative clinical study

Bang Pratima, GD Chandan, Talreja Nidhi¹, Ingale Nitish, Murthy Sankriti, Sangavi Nagaveni, Saraf Shweta

Department of Pedodontics and Preventive Dentistry, VS Dental College and Hospital, Bengaluru, Karnataka, India, ¹Department of Pedodontics and Preventive Dentistry, Lincoln University College, Malaysia

ABSTRACT

Aim: The present study is an attempt to compare and evaluate postoperative assessment of diode laser zinc oxide eugenol (ZOE) pulpotomy and diode laser mineral trioxide aggregate (MTA) pulpotomy procedures in children. **Materials and Methods:** Forty carious primary molars indicated for pulpotomy within the age group of 4-9 years were selected and divided into two groups of 20 each using simple randomization, Group 1: Diode laser MTA and Group 2: Diode laser ZOE pulpotomy. The teeth were evaluated clinically for 1 year at 3, 6, and 12 months interval and radiologically for 6 and 12 months. **Results:** Clinically and radiographically, 100% teeth treated with diode laser MTA and 94% treated with diode laser ZOE were considered successful after 12-month follow-up interval. No significant difference was seen between two groups. **Conclusion:** Despite the success rate, the cost factor of diode laser and MTA could be the limiting factor in its judicious use in pulpotomy procedure.

KEYWORDS: Diode laser, mineral trioxide aggregate, primary molars, pulpotomy, zinc oxide eugenol

Introduction

Evolving dental science has brought about an array of changes in various aspects of dentistry, be it material selection or treatment modalities. We are continuously striving toward achieving perfection which has led to the development of various newer materials which focus mainly on preserving and regenerating the lost tissue. These inventions have undoubtedly elevated our treatment standards but have also raised a question on previous materials that are being used since ages. One such debatable topic that we hear about constantly is pulpotomy. According

Address for correspondence:

Dr. Pratima Bang,
Sunshine Clinic, Opp Shani Mandir, Farshi,
Khamgaon - 444 303, Maharashtra, India.
E-mail: pratimabang@gmail.com

Access this article online

Quick response code



Website:

www.jisppd.com

DOI:

10.4103/JISPPD.JISPPD_1132_17

to the American Academy of Pediatric Dentistry, pulpotomy is described as "complete removal of coronal portion of the dental pulp followed by the placement of suitable dressing or medicament that will promote healing and preserve vitality of the tooth." The term suitable dressing or medicament has created considerable storm in pulpotomy procedure. Formocresol (FC) over the years has still remained the benchmark medicament for pulpotomy procedure due to its consistent results that date back to even more than a century.^[1] However, concerns have been expressed about FC pulpotomy because of observed

This is an open access journal, and articles are distributed under the terms of the Creative Commons Attribution-NonCommercial-ShareAlike 4.0 License, which allows others to remix, tweak, and build upon the work non-commercially, as long as appropriate credit is given and the new creations are licensed under the identical terms.

For reprints contact: reprints@medknow.com

How to cite this article: Pratima B, Chandan GD, Nidhi T, Nitish I, Sankriti M, Nagaveni S, *et al.* Postoperative assessment of diode laser zinc oxide eugenol and mineral trioxide aggregate pulpotomy procedures in children: A comparative clinical study. *J Indian Soc Pedod Prev Dent* 2018;36:308-14.

pulpal response with inflammation and necrosis, cytotoxicity, systemic disturbances, mutagenic and carcinogenic potential, and immunologic responses. Hence, different alternatives have been proposed to maintain partial pulp vitality.^[2]

The various techniques and materials that have been recommended are – glutaraldehyde, ferric sulfate, calcium hydroxide, and laser therapy.^[3] The diode laser represents a whole new way of thinking about dental care. It uses nearly microscopic chips of gallium arsenide or other precious semiconductors to generate coherent light in a very small package. The energy level differences between the conduction and valence band electrons in these semiconductors provide the mechanism for laser action. The diode laser has a much higher overall efficiency, and therefore, is more practical.^[4] It emits an infrared light beam that is capable of producing well-localized ablation of soft tissue through conversion of the laser energy to heat. This interaction is most frequently accompanied by peripheral thermal damage to the tissue and charring at the site of impact.^[5,6] Nevertheless, with appropriate (water) cooling of the tissues, charring can be prevented.^[7] The diode laser is most suited for the pulpotomy technique because of the high absorbance of the wavelength (980 nm) at which energy is produced in tissues such as dental pulp which have very high water content. Furthermore, since this laser is a contact laser, only the soft tissues in immediate contact (micrometer range) with the laser-emitting tip are affected, leaving the remaining tissue unaffected. The laser will have no effect on hard tissues.^[8]

Zinc oxide eugenol (ZOE) is widely used as a base in pulpotomies because of its antibacterial and analgesic properties.^[9] Furthermore, ZOE provides an effective seal, thereby limiting microleakage and subsequent recurrent infection.^[10]

Mineral trioxide aggregate (MTA) is proposed to be used as a pulpotomy agent in primary and permanent teeth. It is also claimed that MTA is a bioinductive material that can induce hard tissue formation in direct contact with the pulp.^[11] It has several desirable properties in terms of its biocompatibility, bioactivity, hydrophilicity, radio-opacity, sealing ability, and low solubility. The most important of these properties in dentistry are its biocompatibility and sealing ability. High biocompatibility encourages optimal healing responses. This has been observed histologically with the formation of new cementum in the periradicular tissue areas and a low inflammatory response with bridge formation in the pulp space.^[12]

Hence, taking into consideration, the properties of the above-mentioned materials, this study has been designed to evaluate the postoperative assessment of diode laser-ZOE and diode laser = MTA pulpotomy procedure in children with the aim of shedding

some light on the materials of pulpotomy and their synergistic relationship.

Materials and Methods

Forty carious primary molars in children which were indicated for pulpotomy within the age group of 4–9 years and who reported to the Department of Pedodontics and Preventive Dentistry, V.S. Dental College and Hospital, Bengaluru were selected for this study and equally divided into two groups using simple randomization.

Group A consisted of 20 primary molars which were treated with diode laser and MTA.

Group B consisted of 20 primary molars which were treated with diode laser and ZOE.

Criteria for tooth selection

Inclusion criteria

1. Restorable carious primary molars with reversible pulpitis and free of clinical or radiographic signs of pulp pathology [Figure 1]
2. Children aged 4–9-years old.

Exclusion criteria

1. Teeth with pathologic root resorption, furcal and periapical radiolucencies
2. Existence of abscess or fistula in relation to the teeth.

Procedure

The study was conducted in the Department of Pedodontics and Preventive Dentistry after obtaining ethical clearance from the institutional ethical committee. Signed written informed consent was obtained from parent/caregiver after explaining them all the positives and negatives of the procedure.

- The selected tooth was anesthetized by local anesthesia using 2% lidocaine with 1:80,000 epinephrine (3M ESPE, St. Paul, MN, USA)

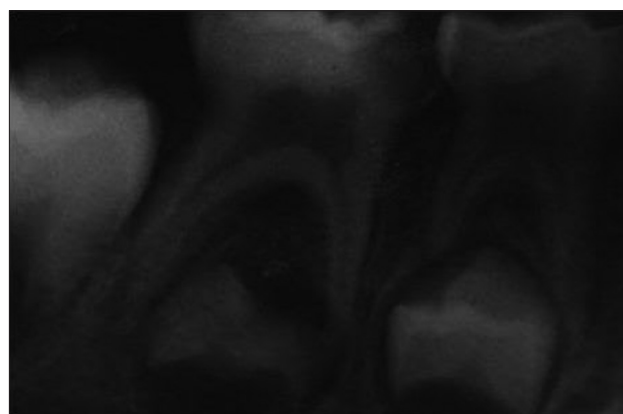


Figure 1: Preoperative radiograph as per the inclusion criteria

Pratima, *et al.*: Diode laser Zinc oxide eugenol and Mineral trioxide aggregate pulpotomy procedures in children

- Isolation with rubber dam was obtained
- All the peripheral-infected caries was excavated followed by excavation of central caries with a sharp spoon excavator and pulp was exposed
- The deroofing of the coronal pulp chamber was done using a high-speed handpiece and diamond round bur ISO # 016 (Dentsply Maillefer; Tulsa, OK, USA) with enough water coolant. The initial hemorrhage was controlled by placing a dry sterile cotton pellet under pressure.

In diode laser pulpotomy (Picasso, AMD Lasers, Indianapolis, USA), the pulp was ablated to the level of the root canal orifice using the 980-nm diode laser set at 2.5–3 W of power with a continuous pulse and using a fiber of 320–400 μm . All patients and clinical staff wore appropriate eye protection during application of the laser. The laser energy was delivered through a 0.5-mm diameter optical fiber in contact with the pulp tissue. Multiple applications were administered until the pulp was ablated and hemostasis was achieved [Figure 2]. Normal saline was used after the laser irradiation to avoid charring. After this, the pulp chamber was observed for brownish to black discoloration of fixed radicular pulpal tissue on the orifice.

Group A: The MTA (ProRoot™, Dentsply, Tulsa, OK, USA) paste was obtained by mixing three parts of powder with one part of water to obtain a putty consistency. This mix was then placed in the pulp chamber and condensed lightly with a moistened cotton pellet. This was followed by a thick creamy mix of ZOE (Kalzinol®, Dentsply, Konstanz, Germany).

Group B: The thick creamy mix of ZOE was placed.

Following this, all the 40 teeth were restored with stainless steel crown (3M ISO-Form, 3M Dental Products, St Paul, MN, USA) cemented in place using glass ionomer cement (Ketac, 3M-ESPE AG, Seefeld, Germany).

Postoperative intraoral periapical digital radiograph was taken. The children were recalled for clinical evaluation at 3, 6, and 12 months and radiological evaluation at 6 and 12 months [Figures 3 and 4]. In the course of follow-up, the pulpal response toward different pulpal medicament were obtained and analyzed for relative success and failure rates with clinical and radiological evidence by two independent examiners who were blinded for the cases which they were asked to examine.

The postoperative clinical success was evaluated for the absence of:

- Pain
- Mobility
- Swelling
- Sinus.

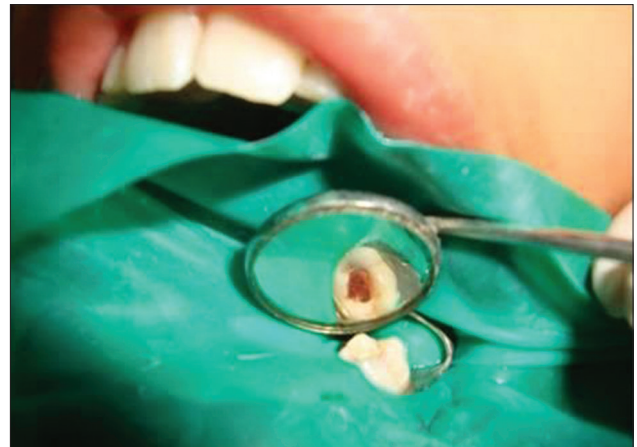

Figure 2: Coronal pulp extirpation done using diode laser

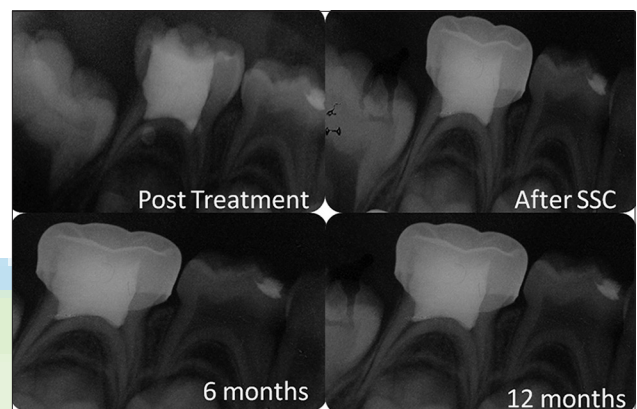


Figure 3: Follow-up radiographs after Diode laser and Zinc oxide eugenol pulpotomy

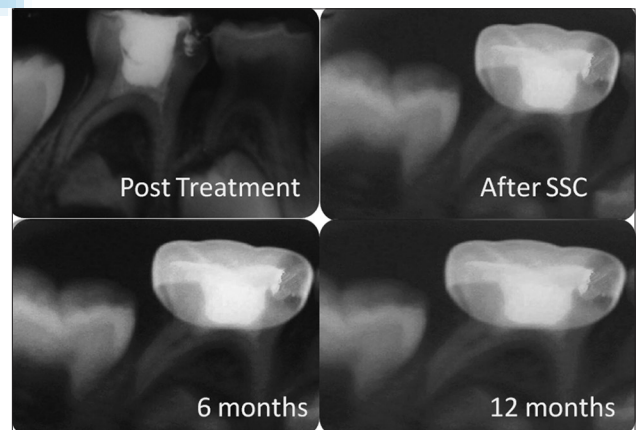


Figure 4: Follow-up radiographs after Diode laser and MTA pulpotomy

The postoperative radiological success was evaluated for the absence of:

- Internal root resorption
- External root resorption
- Periapical or furcation radiolucency
- Widening of periodontal ligament space.

If any one of the above-mentioned parameters was found, it was considered as a failure of pulpotomy medicament and technique and suitable alternative treatment procedure was carried out.

Results

The results were statistically complied and analysis was done using Chi-square test.

The age composition of the two groups is shown in Table 1.

In diode laser MTA group, there was 1 dropout ($n = 19$) and in diode laser ZOE group, there were 3 dropouts ($n = 17$).

Clinical outcome of diode laser mineral trioxide aggregate and diode laser zinc oxide eugenol pulpotomy procedure at 3-month interval

Based on the criteria discussed earlier, success or failure of procedure was determined. Clinically, 100% teeth treated with diode laser MTA and 94% treated with diode laser ZOE were considered successful after 3-month follow-up interval. No significant difference was seen between two groups [Table 2].

Clinical and radiographic outcome of diode laser mineral trioxide aggregate and diode laser zinc oxide eugenol pulpotomy procedure at 6-month interval

Clinically, 100% teeth treated with diode laser MTA and 94% treated with diode laser ZOE were considered successful after 6-months follow-up interval. No significant difference was seen between two groups [Table 3]. Radiographically, 100% teeth treated with diode laser MTA and 94% treated with diode laser ZOE were considered successful after 6-month follow-up. No significant difference was seen between two groups [Table 4].

Clinical and radiographic outcome of diode laser mineral trioxide aggregate and diode laser zinc oxide eugenol pulpotomy procedure at 12-month interval

Clinically, 100% teeth treated with diode laser MTA and 94% treated with diode laser ZOE were considered successful after 12-month follow-up interval. No significant difference was seen between two groups [Table 5]. Radiographically, 100% teeth treated with diode laser MTA and 94% treated with diode laser ZOE were considered successful after 12-month follow-up interval. No significant difference was seen between two groups [Table 6].

Six percent ($n = 1$) of the treated teeth with diode laser ZOE was considered as a failure due to pain.

Table 1: Agewise distribution of samples at the baseline

Age	MTA, n (%)	ZOE, n (%)
4	0	1 (5)
5	4 (20)	6 (30)
6	6 (30)	7 (35)
7	7 (35)	6 (30)
8	2 (10)	0
9	1 (5)	0
Total	20 (100)	20 (100)

MTA=Mineral trioxide aggregate; ZOE=Zinc oxide eugenol

Table 2: Clinical evaluation of diode laser mineral trioxide aggregate and diode laser zinc oxide eugenol pulpotomy procedure at 3 months

3 months clinical	MTA, n (%)	ZOE, n (%)	Mean	SD	χ^2	P
0	19 (100)	16 (94)	0.030	0.167	1.118	0.290
1	0	1 (6)				
Total	19 (100)	17 (100)				

No significant association is observed at 3 months clinical between the material groups ($P>0.05$). MTA=Mineral trioxide aggregate; ZOE=Zinc oxide eugenol; SD=Standard deviation

Table 3: Clinical evaluation of diode laser mineral trioxide aggregate and diode laser zinc oxide eugenol pulpotomy procedure at 6 months

6 months clinical	MTA, n (%)	ZOE, n (%)	Mean	SD	χ^2	P
0	19 (100)	16 (94)	0.030	0.167	1.118	0.290
1	0	1 (6)				
Total	19 (100)	17 (100)				

No significant association is observed at 6 months clinical between the material groups ($P>0.05$). MTA=Mineral trioxide aggregate; ZOE=Zinc oxide eugenol; SD=Standard deviation

Table 4: Radiographic evaluation of diode laser mineral trioxide aggregate and diode laser zinc oxide eugenol pulpotomy procedure at 6 months

6 months r/g	MTA, n (%)	ZOE, n (%)	Mean	SD	χ^2	P
0	19 (100)	16 (94)	0.030	0.167	1.118	0.290
1	0	1 (6)				
Total	19 (100)	17 (100)				

No significant association is observed at 6 months clinical between the material groups ($P>0.05$). MTA=Mineral trioxide aggregate; ZOE=Zinc oxide eugenol; SD=Standard deviation

In this present study, there was no statistically significant difference between the two groups. However, with diode laser and MTA, there was no failure, whereas one failure was seen with the diode laser ZOE pulpotomy.

Discussion

No area in the field of pediatric dentistry has been more controversial than pulp therapy. In particular,

Table 5: Clinical evaluation of diode laser mineral trioxide aggregate and diode laser zinc oxide eugenol pulpotomy procedure at 12 months

12 months clinical	MTA, n (%)	ZOE, n (%)	Mean	SD	χ^2	P
0	19 (100)	16 (94)	0.030	0.167	1.118	0.290
1	0	1 (6)				
Total	19 (100)	17 (100)				

No significant association is observed at 12 months clinical between the material groups ($P>0.05$). MTA=Mineral trioxide aggregate; ZOE=Zinc oxide eugenol; SD=Standard deviation

Table 6: Radiographic evaluation of diode laser mineral trioxide aggregate and diode laser zinc oxide eugenol pulpotomy procedure at 12 months

12 months r/g	MTA, n (%)	ZOE, n (%)	Mean	SD	χ^2	P
0	19 (100)	16 (94)	0.030	0.167	1.118	0.290
1	0	1 (6)				
Total	19 (100)	17 (100)				

No significant association is observed at 12 months r/g between the material groups ($P>0.05$). MTA=Mineral trioxide aggregate; ZOE=Zinc oxide eugenol; SD=Standard deviation

the vital pulpotomy procedure has always been the topic of debate.^[13] The procedures of pulpotomy for the primary dentition have been developed along three lines: devitalization, preservation, and regeneration. Devitalization, where the intent is to destroy vital tissue, is typified by FC, electrocautery, and laser. Preservation, where the retention of maximum vital tissue with no induction of reparative dentin, is exemplified by glutaraldehyde and ferric sulfate. Regeneration, where the stimulation of dentin bridge, has long been associated with calcium hydroxide and presently MTA. Of the three categories, regeneration is expected to develop most rapidly in the coming years.

Following the initial trial by Redig,^[14] the 5-min FC is still in use today despite so many controversies regarding its use.^[15] However, the only rationale for using FC is empirical – “It succeeds more often than it fails.”^[16] Even with its overwhelming success over the years as a pulpotomy agent, it has received lots of criticism, which have shown formaldehyde to be toxic, mutagenic, and carcinogenic.^[17] In an attempt to avoid chemicals altogether, another form of devitalization pulpotomy technique, laser was given the importance. Ideally, laser irradiation would create a superficial zone of coagulation necrosis that remained compatible with the underlying tissue and that isolated the pulp from the vagaries of the subbase.^[16]

Thesecond approach to pulpotomy treatment in primary teeth is preservation (minimum devitalization), which indicates an attempt to maintain the maximum amount of the vital tissue. ZOE was the first agent to be used for preservation.^[16] Although ZOE is an obtundant, it does not apparently suppress metabolism adequately or self-limit its irritative properties. Chronic inflammation

persists for extended periods of time after application of ZOE causing internal resorption.^[18]

The third approach to pulpotomy treatment in primary teeth is regeneration. The most important objective of regeneration is to attain vital tissue and stimulate reparative dentine formation,^[13] which is based on sound biological principles. Calcium hydroxide was the first agent used in pulpotomies, but it is not the therapy of choice for pulpotomies in the primary dentition because of increased incidence of internal resorption.^[19]

MTA has been tested as a regenerative material on amputated pulp tissue in cases of root-end filling and root perforations. *In vitro* and *in vivo* studies have shown that MTA possesses a multitude of properties, alkaline pH of 12.5, good biocompatibility, and low-level toxicity, which may eliminate the inflammation of the soft tissues with which it comes into contact. It also provides sealing, avoiding the infiltration of bacteria, toxins, and stains and has proven to induce the formation of bone tissue, cementum, and periodontal membrane in cases of root end formation or filling.^[20]

Hence, to see whether a combination of preservation and regeneration technique works better than one alone, the present *in vivo* study was carried out, taking into account that success of pulpotomy not only depends on the materials but also on the case selection and technique.

In the present clinical study, age group considered was 4–9 years irrespective of the sex of the children. This age group was selected considering that children below 4 years of age might not be cooperative and above 9 years may tend to exhibit physiologic root resorption.^[21] The postoperative clinical evaluation of diode laser MTA pulpotomy medicament group was free from pain (100% success) throughout the follow-up period which could be attributed to the excellent sealing ability and hard tissue formation of MTA, but diode laser ZOE pulpotomy group showed pain in one case at 3 months which could be attributed to the poor sealing ability of ZOE [Tables 3, 4, and 6]. Caicedo *et al.*^[22] reported one case with postoperative pain in MTA pulpotomized tooth. Gupta *et al.*,^[23] Vahid Golpayegani *et al.*,^[24] and Durmus *et al.*^[25] reported 100% success rate after laser pulpotomy. Saltzman *et al.*^[8] reported no pain in diode laser MTA group. Eidelman *et al.*^[26] and Agamy *et al.*^[2] reported 100% success rate after MTA pulpotomy. Diode laser ZOE and diode laser MTA group remained free of pathologic mobility [Tables 3, 4, and 6]. Gupta *et al.*,^[23] Vahid Golpayegani *et al.*,^[24] and Durmus *et al.*^[25] reported no pathologic mobility with laser pulpotomy.

Occurrence of swelling postoperatively was absent in the two groups which can be to a great extent attributed to proper case selection and tissue healing

abilities of the medicaments used [Tables 3, 4, and 6]. Gupta *et al.*,^[23] Vahid Golpayegani *et al.*,^[24] Durmus *et al.*^[25] reported no swelling with laser pulpotomy. Caicedo *et al.*^[22] who reported one case of swelling in his MTA group. Swelling may be attributed to chronic inflammation of the pulp and periapical tissue leading to edema postoperative evaluation for sinus showed both groups were free from sinus or fistulation [Tables 3, 4, and 6]. Gupta *et al.*,^[23] Vahid Golpayegani *et al.*,^[24] and Durmus *et al.*^[25] reported no sinus with laser pulpotomy which is in accordance with the study. Caicedo *et al.*^[22] reported one case of fistulation postoperatively.

In the present study, no pathologic resorption, furcal or periapical radiolucency was seen. Gupta *et al.*^[23] showed no failure in laser pulpotomy group [Tables 4 and 6]. Jayam *et al.*^[1] showed 100% success rate with MTA pulpotomy. Vahid Golpayegani *et al.*^[24] reported signs of periapical radiolucency in two cases with low-level laser pulpotomy procedure. Saltzman *et al.*^[8] reported six of the laser-MTA exhibited furcal and/or periapical radiolucencies with or without pathologic root resorption. Caicedo *et al.*^[22] also reported furcal radiolucency in one case in MTA group. Agamy *et al.*^[2] reported furcal radiolucency in 4 cases after 12-month evaluation with the first case showing radiolucency at the 3-month recall. Internal resorption was not seen in both the groups [Tables 4 and 6]. This was in accordance with a study done by Gupta *et al.*^[23] and Vahid Golpayegani *et al.*^[24] study using laser. Jayam *et al.*^[1] showed 100% success rate with MTA pulpotomy.

Postoperative evaluation for external root resorption shows that it was absent in both groups [Tables 4 and 6]. This was in accordance with a study done by Gupta *et al.*,^[23] Saltzman *et al.*,^[8] Vahid Golpayegani *et al.*,^[24] and Durmus *et al.*^[25] study using laser. Both the groups, diode laser MTA and diode laser ZOE, were free of widening of periodontal ligament space throughout the follow-up period of 1 year [Tables 4 and 6]. This was in accordance with a study done by Gupta *et al.*,^[23] Saltzman *et al.*,^[8] Vahid Golpayegani *et al.*,^[24] and Durmus *et al.*^[25] study using laser.

In the present study, overall clinical and radiographic success remained at 100% for diode laser MTA pulpotomy, while 94% for diode laser ZOE pulpotomy procedure. The clinical and radiological success of pulpotomies with MTA in the present study is closely comparable to that of the studies of Jabbarifar *et al.*,^[27] Farsi *et al.*,^[28] Naik and Hegde,^[29] Eidelman *et al.*,^[26] Caicedo *et al.*,^[22] Holan *et al.*,^[30] and Cuisia *et al.*^[31] In their narrative review of evidence-based report on various MTA pulpotomy studies, clinically an average success rate of 98.5% and radiologically 98% of success rate was found.

The failure of pulpotomy treatment in primary molars could be attributed to the number of factors, one of

which may be clinical errors in diagnosis and selection of the case; for example, chronically inflamed radicular pulp was believed to be noninflamed. Laser irradiation caused carbonization, necrosis, and infiltration of inflammation cells, edema in the pulp tissue that could be a reason for pathology due to laser. Other possible reason could be the use of ZOE as sub-base which is in direct contact with the highly perfused environment of pulp and undergo hydrolysis of the zinc eugenolate to yield free eugenol.

Thus, a further long-term follow-up work with a larger sample size is recommended to corroborate the findings of our study.

Conclusion

This study concluded that there are no significant differences in diode laser MTA and diode laser ZOE groups. Apparently, diode laser MTA did not show any failure so might prove better in a study conducted with larger patient pool. However, cost is a major limiting factor in the Indian Scenario which would limit the judicious use of preservation and regeneration together.

Financial support and sponsorship

Nil.

Conflicts of interest

There are no conflicts of interest.

References

1. Jayam C, Mitra M, Mishra J, Bhattacharya B, Jana B. Evaluation and comparison of white mineral trioxide aggregate and formocresol medicaments in primary tooth pulpotomy: Clinical and radiographic study. *J Indian Soc Pedod Prev Dent* 2014;32:13-8.
2. Agamy HA, Bakry NS, Mounir MM, Avery DR. Comparison of mineral trioxide aggregate and formocresol as pulp-capping agents in pulpotomized primary teeth. *Pediatr Dent* 2004;26:302-9.
3. De Coster P, Rajasekharan S, Martens L. Laser-assisted pulpotomy in primary teeth: A systematic review. *Int J Paediatr Dent* 2013;23:389-99.
4. Hicks MJ, Barr ES, Flaitz CM. Formocresol pulpotomies in primary molars: A radiographic study in a pediatric dentistry practice. *J Pedod* 1986;10:331-9.
5. Roberts JF. Treatment of vital and non-vital primary molar teeth by one-stage formocresol pulpotomy: Clinical success and effect upon age at exfoliation. *Int J Paediatr Dent* 1996;6:111-5.
6. Ranly DM. Assessment of the systemic distribution and toxicity of formaldehyde following pulpotomy treatment: Part one. *ASDC J Dent Child* 1985;52:431-4.
7. Ranly DM, Horn D. Assessment of the systemic distribution and toxicity of formaldehyde following pulpotomy treatment: Part two. *ASDC J Dent Child* 1987;54:40-4.

Pratima, *et al.*: Diode laser Zinc oxide eugenol and Mineral trioxide aggregate pulpotomy procedures in children

8. Saltzman B, Sigal M, Clokie C, Rukavina J, Titley K, Kulkarni GV, *et al.* Assessment of a novel alternative to conventional formocresol-zinc oxide eugenol pulpotomy for the treatment of pulpally involved human primary teeth: Diode laser-mineral trioxide aggregate pulpotomy. *Int J Paediatr Dent* 2005;15:437-47.
9. Tchaou WS, Turng BF, Minah GE, Coll JA. *In vitro* inhibition of bacteria from root canals of primary teeth by various dental materials. *Pediatr Dent* 1995;17:351-5.
10. Cotes O, Boj JR, Canalda C, Carreras M. Pulpal tissue reaction to formocresol vs. Ferric sulfate in pulpotomized rat teeth. *J Clin Pediatr Dent* 1997;21:247-53.
11. Shirvani A, Hassanizadeh R, Asgary S. Mineral trioxide aggregate vs. Calcium hydroxide in primary molar pulpotomy: A Systematic review. *Iran Endod J* 2014;9:83-8.
12. Tawil PZ, Duggan DJ, Galicia JC. Mineral trioxide aggregate (MTA): Its history, composition, and clinical applications. *Compend Contin Educ Dent* 2015;36:247-52.
13. Prabhu NT, Munshi AK. Clinical, radiographic and histological observations of the radicular pulp following “feracrylum” pulpotomy. *J Clin Pediatr Dent* 1997;21:151-6.
14. Redig DF. A comparison and evaluation of two formocresol pulpotomy technics utilizing “Buckley’s” formocresol. *J Dent Child* 1968;35:22-30.
15. Lewis B. Formaldehyde in dentistry: A review for the millennium. *J Clin Pediatr Dent* 1998;22:167-77.
16. Ranly DM. Pulpotomy therapy in primary teeth: New modalities for old rationales. *Pediatr Dent* 1994;16:403-9.
17. Lewis BB, Chestner SB. Formaldehyde in dentistry: A review of mutagenic and carcinogenic potential. *J Am Dent Assoc* 1981;103:429-34.
18. Goerig AC, Payne TF, del Rio CE. The pulpal response to ZOE with stock eugenol versus ZOE with purified eugenol. *Oral Surg Oral Med Oral Pathol* 1980;50:557-62.
19. Berson RB, Good DI. Pulpotomy and Pulpectomy for primary teeth. In: Stewart RE, Barber TK, Troutman KC, Wei SHY, Eds. *Pediatric Dentistry: Scientific Foundation and Clinical Practice*. St Louis: Mosby; 1981. p. 917-26.
20. Maroto M, Barbería E, Planells P, Garcia Godoy F. Dentin bridge formation after mineral trioxide aggregate (MTA) pulpotomies in primary teeth. *Am J Dent* 2005;18:151-4.
21. Godhi B, Sood PB, Sharma A. Effects of mineral trioxide aggregate and formocresol on vital pulp after pulpotomy of primary molars: An *in vivo* study. *Contemp Clin Dent* 2011;2:296-301.
22. Caicedo R, Abbott PV, Alongi DJ, Alarcon MY. Clinical, radiographic and histological analysis of the effects of mineral trioxide aggregate used in direct pulp capping and pulpotomies of primary teeth. *Aust Dent J* 2006;51:297-305.
23. Gupta G, Rana V, Srivastava N, Chandna P. Laser pulpotomy – An Effective alternative to conventional techniques: A 12 Months Clinicoradiographic Study. *Int J Clin Pediatr Dent* 2015;8:18-21.
24. Vahid Golpayegani M, Ansari G, Tadayon N, Shams SH, Mir M. Low-level laser therapy for pulpotomy treatment of primary molars. *J Dent* 2009;6:4.
25. Durmus B, Tanboga I. *In vivo* evaluation of the treatment outcome of pulpotomy in primary molars using diode laser, formocresol, and ferric sulphate. *Photomed Laser Surg* 2014;32:289-95.
26. Eidelman E, Holan G, Fuks AB. Mineral trioxide aggregate vs. Formocresol in pulpotomized primary molars: A preliminary report. *Pediatr Dent* 2001;23:15-8.
27. Jabbarifar SE, Khademi AA, Ghasemi DD. Success rate of formocresol pulpotomy versus mineral trioxide aggregate in human primary molar tooth. *J Res Med Sci* 2004;6:55-8.
28. Farsi N, Alamoudi N, Balto K, Al Mushayt A. Clinical assessment of mineral trioxide aggregate (MTA) as direct pulp capping in young permanent teeth. *J Clin Pediatr Dent* 2006;31:72-6.
29. Naik S, Hegde AH. Mineral trioxide aggregate as a pulpotomy agent in primary molars: An *in vivo* study. *J Indian Soc Pedod Prev Dent* 2005;23:13-6.
30. Holan G, Eidelman E, Fuks AB. Long-term evaluation of pulpotomy in primary molars using mineral trioxide aggregate or formocresol. *Pediatr Dent* 2005;27:129-36.
31. Cuisia ZE, Musselman R, Schneider P, Dumett CJ. A study of mineral trioxide aggregate pulpotomies in primary molars. *Ped Dent* 2001;23:168.